



LETTER TO THE EDITOR

Systemic immunomodulatory effects of *Polypodium leucotomos* as an adjuvant to PUVA therapy in generalized vitiligo: A pilot study

KEYWORDS

Adjuvant;
 Immunomodulation;
*Polypodium
 leucotomos*;
 PUVA;
 Vitiligo

Although extensive research has been done to improve the treatment of vitiligo, an universal effective treatment for vitiligo is not yet available [1]. PUVA therapy has demonstrated to have immunomodulatory effects, mainly in the T lymphocyte compartment but has several adverse effects, such as skin cancer risk [2,3]. The optimization of PUVA therapy is a relevant clinical objective in the management of vitiligo patients.

Polypodium leucotomos (PL) extract has demonstrated to have relevant photoprotective effects in humans [4,5] and animal models [6]. These biological effects may be involved in the action mechanism of PL on vitiligo patients, and could explain the enhancement of the pigmentary response of conventional PUVA by PL when this was used as adjuvant treatment in vitiligo patients [4].

In order to optimize PUVA treatment for management of vitiligo patients, we therefore investigated potential immunomodulatory effects of PUVA associated with PL. For this purpose, a pilot randomized, double-blind, placebo-controlled, clinical trial designed to study effects of PUVA + PL on T lymphocytes from 19 generalized vitiligo patients was conducted (Table 1). At baseline (before first PUVA session) and after 12 weeks of treatment (before of the last PUVA session), peripheral blood both from patients and from each corresponding control was withdrawn. Repigmentation response was evaluated

by three independent dermatologists at 12 weeks and graded as none or minimal (<25%), mild (25–50%) and moderate to excellent (>50%). Peripheral blood mononuclear cells (PBMC) isolation, immunofluorescence and proliferative response (PR) assays have been previously described [7].

At baseline we observed an abnormal in vivo activation of T lymphocytes in patients (increased CD25 and HLA-DR expression and decreased percentage of CD8+CD45RO+ cells) (Fig. 1, Panel A). The percentages and absolute counts of CD56+CD3–, CD16+, CD2+, CD3+, CD3+CD4+, CD4+CD45RA+, CD4+CD45RO+, CD3+CD8+, CD8+CD45RA+, CD11a+, CD11b+, CD19+ and CD45+ cells were similar in patients and healthy controls (data not shown). Subjects treated with PUVA + placebo did not significantly change any of the parameters analyzed, however, in patients receiving PUVA + PL, we observed a significant increase in the percentage of CD8+CD45RA+ subset (24.5 ± 1.5 to 33.7 ± 2.6) with a significant decrease in the percentage of CD25+, HLA-DR+ and CD8+CD45RO+ lymphocytes when compared to baseline. As shown in Panel B, there was no significant difference in the PR of PBMC between patients and healthy controls. Whereas no significant change in the PR was seen after treatment with PUVA + placebo, the treatment with PUVA + PL provoked a significant decrease in the PR as compared to baseline and controls. The in vitro addition of ionomycin or IL-2 significantly increased PR from all subjects when compared to those found in the presence of anti-CD3+TPA alone. The addition of IL-4 did not induce significant modifications in the PR of patients treated with PUVA + placebo, but significantly reduced the PR of the group treated with PUVA + PL with respect to that found in presence of anti-CD3+TPA alone.

We found that the percentage of subjects with a skin repigmentation >50% was significantly higher in arm of PUVA + PL than in the arm with PUVA + placebo. The PUVA treatment significantly decreased the percentages of CD3+CD25+ and CD8+CD45RO+ cells in the patient group with a mild repigmentation response (Panel C). We also found that the PUVA

Table 1 Profile, treatment and clinical response of vitiligo patients

Patients number	Age (years)/sex	Duration of disease (years)	Family history of vitiligo	Adjuvant to PUVA treatment	Clinical response after PUVA therapy
1	54/female	10.57	No	Placebo	None or minimal
2	27/male	9.04	No	Placebo	None or minimal
3	50/female	3.04	No	Placebo	Mild
4	33/male	9.18	No	Placebo	None or minimal
5	20/male	13.20	No	Placebo	Mild
6	50/female	6.06	Yes	Placebo	Mild
7	24/male	6.24	Yes	Placebo	None or minimal
8	59/female	12.35	No	Placebo	Mild
9	45/female	4.35	No	Placebo	None or minimal
10	35/male	23.55	No	PL	None or minimal
11	19/female	6.55	No	PL	Mild
12	38/male	2.57	No	PL	Moderate to excellent
13	42/female	15.57	No	PL	Moderate to excellent
14	71/male	2.57	No	PL	Moderate to excellent
15	50/male	13.97	No	PL	Mild
16	26/female	9.04	No	PL	Mild
17	47/female	13.04	No	PL	Moderate to excellent
18	20/female	3.08	Yes	PL	None or minimal
19	38/male	1.24	No	PL	Moderate to excellent

A computer program makes the assignment in placebo or PL arms. All patients had generalized vitiligo for a mean \pm S.D. of 8.69 ± 5.69 years, all patients had skin phototype II–III. No acral and/or segmental vitiligo patients were included in this study. None of the patients had another significant intercurrent disease of the immune system, such as AIDS, congenital immunodeficiencies, lymphoma, leukemia or myelodysplastic syndrome, autoimmune diseases, active infection, history of malignancy, psychiatric or severe organic diseases. None of the patients had previously received treatment with PUVA, steroidal drugs, cytokines or other immunomodulators for at least 6 months. Patients with acral vitiligo were excluded as well. After treatment, the classification of vitiligo patients was similar although we found improve in the repigmentation in some patients treated with PUVA. The study followed the principles of Declaration of Helsinki. All patients were treated with a combination of PUVA + PL or PUVA + placebo for 12 consecutive weeks. 8-Methoxypsoralen was given 2 h before each session of UVA irradiation at a dose of 0.6 mg/kg body weight. UVA irradiation was applied with a solar simulator which emits 90% UVA and 10% UVB irradiation. The initial irradiation dose was 0.5 J/cm² with subsequent increases of 0.5 J/cm² in order to reach a moderate and asymptomatic erythema (mean dose of 8 J/cm²). The frequency of PUVA sessions in both arms of the study was three times per week. The cumulative UVA dose after 12 weeks was 324 J/cm², similar in both groups of patients. PL (Difur[®], Industrial Farmaceutica Cantabria [IFC], Madrid, Spain) or placebo (starch) were given orally at a dose of 720 mg/day. An additional dose of 720 mg was given 1 h before irradiation.

treatment significantly decreased the percentage of CD3+CD25+, CD3+HLADR+ and CD8+CD45RO+ cells in the patient group with a moderate to excellent response. The treatment with PUVA in patients with a mild/moderate to excellent repigmentation response provoked a significant decrease in the PR to T cell mitogens as compared to baseline and healthy controls (Panel D). Furthermore, this significant reduction was also observed in the presence of ionomycin, IL-2 or IL-4 in the culture medium. For all the patients as a whole, we observed a significant correlation between the clinical response and the percentage of CD3+CD25+ cells (correlation coefficient = -0.493).

The normal PR of PBMC from generalized vitiligo patients differs from those seen in other autoimmune diseases with similar activation of T lymphocytes [7]. It might be argued that the alteration of the T lymphocyte compartment from vitiligo patients does not reach the levels of functional abnormality observed for us in other systemic dis-

eases [7]. PUVA therapy induces a cell cycle arrest and subsequent apoptosis in T lymphocytes from vitiligo patients [8]. Our data indicate that PUVA therapy is not able to suppress the abnormal in vivo activation of the T lymphocyte nor has it functional effects on the PR of PBMC. In contrast, PUVA + PL therapy normalized the expression of activation markers by T cells and it suppressed the proliferation of PBMC to mitogens. These effects of the adjuvant use of PL agree with its known biological effects, since PL has demonstrated to have immunomodulatory activity upon T cell activation [9].

The relevance of the immunosuppression in the treatment of vitiligo has been described but the toxicity of the analyzed immunosuppressive drugs, such as cyclosporine or steroids, as well as the transitory effects of these treatments have limited their clinical use. The increased long-term skin cancer risk observed in PUVA treated patients is also a limiting factor in this treatment modality in vitiligo patients. In this study, neither significant

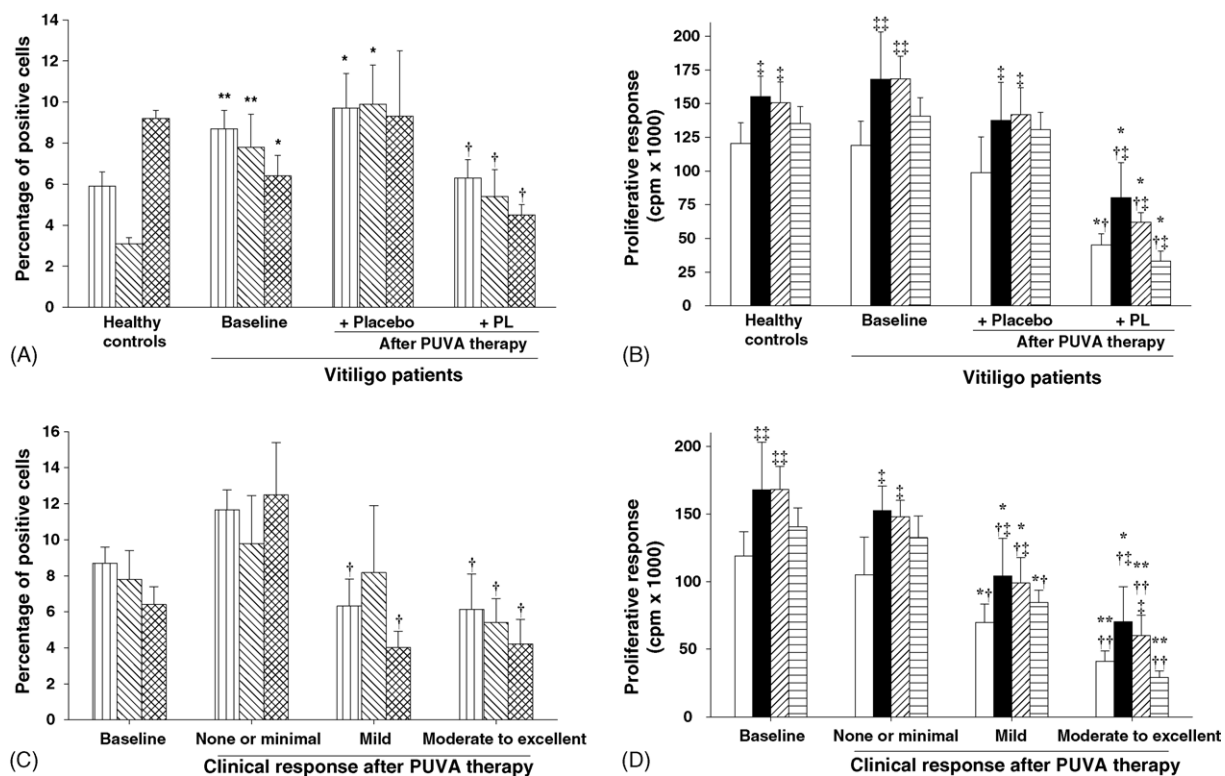


Fig. 1 Immunophenotype and proliferative responses of PBMC from healthy controls and vitiligo patients. Panels A and B show immunophenotype and proliferative responses of PBMC from healthy controls ($n = 19$) and those from vitiligo patients at baseline ($n = 19$) and after PUVA + placebo treatment ($n = 9$) or PUVA + PL treatment ($n = 10$). Panels C and D show immunophenotype and proliferative responses of PBMC from vitiligo patients classified according to clinical response, none or minimal ($n = 7$), mild ($n = 7$) and moderate to excellent ($n = 5$) at baseline and after treatment. Expression of CD25+ (□), HLA-DR+ (▨) and CD8+CD45RO+ (▩) and proliferative responses in presence of anti-CD3+TPA (□), and after the addition of ionomycin (■), IL-2 (▨) or IL-4 (▩). Data are shown in percentage as mean \pm S.D. (Panels A and C) or in cpm as mean \pm S.E.M. (Panels B and D). * $p < 0.05$ vs. healthy controls; Mann-Whitney U -test. ** $p < 0.01$ vs. healthy controls; Mann-Whitney U -test. † $p < 0.05$, indicated significant decrease from baseline; Wilcoxon Signed Ranks test. †† $p < 0.01$, indicated significant decrease from baseline; Wilcoxon Signed Ranks test. ‡ $p < 0.05$, indicate significant differences compared to anti-CD3+TPA polyclonal stimulation alone; Wilcoxon Signed Ranks test.

phototoxic side effects nor carcinogenesis were found in both groups of patients. The immunosuppressive effects observed with PUVA + PL treatment, might explain the higher rate of patients with moderate to excellent repigmentation. These clinical results agree with previous reports of acceleration and increase in the pigmentary response of conventional PUVA therapy in vitiligo patients (extensive instead of extended) treated with oral PL [4]. The immunomodulatory effects seen with the adjuvant use of PL in PUVA treatment of vitiligo patients, and the clinical results observed, justify further clinical trials with large patient populations.

Acknowledgments

The reagents used in our study, placebo and *Polypodium leucotomos*, were graciously provided by its manufacturer IFC, Madrid, Spain. All authors

declare any commercial or financial interest including support from drug companies that might be involved in the treatment of vitiligo. Melchor Alvarez-Mon and Salvador Gonzalez are consultants for IFC. This work was partially supported by grants from the CICYT (C001999-AX131), Feder (2FD1997-1950) and FIS (00/0806), Spain.

References

- [1] Morison WL. Psoralen ultraviolet A therapy in 2004. *Photodermatol Photoimmunol Photomed* 2004;20:315–20.
- [2] Tokura Y, Seo N, Yagi H, et al. Treatment of T lymphocytes with 8-methoxypsoralen plus ultraviolet A induces transient but biologically active Th1-skewing cytokine production. *J Invest Dermatol* 1999;113:202–8.
- [3] Stern RS. The risk of melanoma in association with long-term exposure to PUVA. *J Am Acad Dermatol* 2001;44:755–61.
- [4] Gonzalez S, Pathak MA. Inhibition of ultraviolet-induced formation of reactive oxygen species, lipid peroxidation,

- erythema and skin photosensitization by *Polypodium leucotomos*. *Photodermatol Photoimmunol Photomed* 1996;12:45–56.
- [5] Gonzalez S, Pathak MA, Cuevas J, et al. Topical or oral administration with an extract of *Polypodium leucotomos* prevents acute sunburn and psoralen-induced phototoxic reactions as well as depletion of Langerhans cells in human skin. *Photodermatol Photoimmunol Photomed* 1997;13:50–60.
- [6] Alcaraz MV, Pathak MA, Rius F, et al. An extract of *Polypodium leucotomos* appears to minimize certain photoaging changes in a hairless albino mouse animal model. A pilot study. *Photodermatol Photoimmunol Photomed* 1999;15:120–6.
- [7] Hernandez-Fuentes MP, Reyes E, Prieto A, et al. Defective proliferative response of T lymphocytes from patients with inactive systemic lupus erythematosus. *J Rheumatol* 1999;26:1518–26.
- [8] Johnson R, Staiano-Coico L, Austin L, et al. PUVA treatment selectively induces a cell cycle block and subsequent apoptosis in human T-lymphocytes. *Photochem Photobiol* 1996;63:566–71.
- [9] Rayward J, Villarrubia VG, Guillen C, et al. An extract of the fern *Polypodium leucotomos* inhibits human peripheral blood mononuclear cells proliferation in vitro. *Int J Immunopharmacol* 1997;9:9–14.

Eduardo Reyes*

Pedro Jaén

Elena de las Heras

Flavio Carrión

Melchor Álvarez-Mon

*Laboratory of Immune System Disease and Oncology,
National Biotechnology Associated Unit (CNB-CSIC),
Department of Medicine, University of Alcalá,
Madrid, Spain*

Pedro Jaén

Ester de Eusebio

*Dermatology Service, Hospital of Guadalajara,
Guadalajara, Spain*

Jesús Cuevas

*Pathology Service, Hospital of Guadalajara,
Guadalajara, Spain*

Salvador González

*Wellman Laboratories of Photomedicine,
Department of Dermatology, Massachusetts General
Hospital, Harvard Medical School, Boston, MA, USA*

Vicente G. Villarrubia

*Department of Immunology, I.F. Cantabria,
Madrid, Spain*

Melchor Álvarez-Mon

*Medicine and Immune System Diseases
and Oncology Service, University Hospital
Principe de Asturias, University of Alcalá,
Madrid, Spain*

*Corresponding author. Tel.: +34 91 8854888;

fax: +34 91 8854526

E-mail address: eduardo.reyes@uah.es (E. Reyes)

14 June 2005

Available online at www.sciencedirect.com

SCIENCE @ DIRECT®